

# Appalling Adverse Effects of Amlodipine in a Chronic Kidney Disease Patient: A Case of Drug-Induced Gingival Overgrowth

Geon Pauly, Roopashri Rajesh Kashyap, Raghavendra Kini, Prasanna Kumar Rao, Gowri P Bhandarkar, Devika Shetty

Department of Oral Medicine and Radiology, A J Institute of Dental Sciences, Kuntikana, NH - 66, Mangalore - 575004, Karnataka, INDIA.

## ABSTRACT

Calcium channel blockers have been widely used in clinical practice because of their antihypertensive capacity. Prevention of renal damage is a very important aim of antihypertensive therapy. This is particularly so taking into account the high prevalence of chronic kidney disease (CKD) in the general population. Medications taken for medical conditions often manifest local to systemic side-effects including the oral cavity. Gingival overgrowth is one such unwanted adverse effect. It is a well-documented side effect associated with three major classes of drugs: anticonvulsants, calcium channel blockers (CCB), and immune-suppressants. Despite a greater understanding of pathogenesis of drug induced gingival overgrowth (DIGO), its treatment still remains a challenge for the dental practitioner and treatment is still largely limited to maintenance of improved level of

oral hygiene and surgical removal of overgrown tissue. There is a need for the dental surgeons to discuss this issue with their medical colleagues and to practice statutory care while prescribing the drugs associated with gingival overgrowth.

**Key words:** Renal insufficiency, Immunosuppressive agents, Gingival overgrowth.

## Correspondence:

**Devika Shetty,**

Department of Oral Medicine and Radiology, A J Institute of Dental Sciences, Kuntikana, NH - 66, Mangalore - 575004, Karnataka, INDIA.

Email: dshetty@gmail.com

DOI: 10.5530/PTB.2018.4.3

## INTRODUCTION

An overgrowth or increase in size of the gingiva is termed as gingival enlargement, also known as gingival hyperplasia, gingival overgrowth or gingival hypertrophy. Gingival overgrowth is a well-known consequence of administration of certain group of drugs.<sup>1</sup> Gingival overgrowth is caused by both external as well as intrinsic etiological factors. Clinical symptoms include enlargement of the volume of the vertical and horizontal dimensions of the gingival margin and gingival papilla.<sup>2</sup>

Amlodipine induced gingival overgrowth was first reported by Seymour *et al.*<sup>3</sup> and there have been only few reported associations of gingival overgrowth with this drug. Amlodipine such as nifedipine can be detected in gingival crevicular fluid. Gingival sequestration of amlodipine associated with gingival hyperplasia has also been reported.<sup>4</sup> Hereby, we report a case of DIGO in a 31-year-old CKD patient with a history of intake of amlodipine.

## CASE REPORT

A 31-year-old female patient was referred to our department with a chief complaint of 'swollen gums in the oral cavity' which was progressively increasing in nature [Figure 1-A]. Past medical history revealed she was diagnosed with chronic kidney disease about 1 year back and started receiving amlodipine (10mg/daily) since the past 6 months. The painless and gradual over-growth of gingiva was first noticed by the patient about 4 months prior.

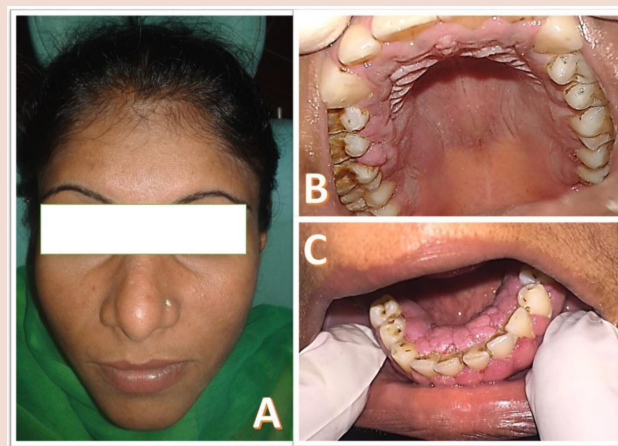Clinical examination revealed gingival overgrowth with rolled out margins and lobulated papillae found in the maxillary arch restricted only to the palatal aspect [Figure 1-B] and the mandibular arch with prominence on both the labial and the lingual sides, with particularly pronounced overgrowth on the lingual aspect [Figure 1-C]. Generalized pseudo pockets measuring 3 mm to 8 mm and generalized bleeding on probing were present. The lack of true periodontal pockets was a prominent feature of gingival overgrowth indicating enlargement of gingiva. Oral hygiene was poor with excessive local deposits as the patient was unable to maintain good oral hygiene. Treatment plan consisted of initial phase therapy with thorough oral prophylaxis (Scaling and Root planning).

And as the patient was not willing for surgical excision, she was put on alternate medication (Losartan Potassium 25mg/day) which resulted in regression of the growth over a span of 3-4 months.

## DISCUSSION

Gingival enlargement is the painless enlargement of buccal and lingual gingival.<sup>5</sup> Many factors contribute to its development including: plaque control, periodontal variable, medications and their relative dose, age, sex and genetic factors. In 1994, Bokenkamp *et al.*<sup>6</sup> graded gingival overgrowth as:<sup>7</sup>

- Grade 0: No sign of enlargement
- Grade 1: Enlargement confined to dental papilla



**Figure 1: A – Straight Facial Profile. B – DIGO of the Maxillary Arch. C – DIGO of the Mandibular Arch.**

- Grade 2: Enlargement involving dental papilla and marginal gingiva
- Grade 3: Enlargement covering three-quarters of crown of tooth or more<sup>7</sup>

The drugs causing DIGO can be discussed as three major groups based on their therapeutic action: Anticonvulsants (phenytoin), immunosuppressive agents (cyclosporine A) and calcium channel blockers. Among calcium channel blockers, the ones causing gingival hyperplasia in order of frequency are nifedipine (6.3%), verapamil (4.1%) and amlodipine with lower rates (1.3% to 3.3%) which makes our case strongly on the rare side.<sup>8</sup>

Amlodipine is a long-acting calcium channel blocker agent from the dihydropyridine group, which is used for the treatment of hypertension and angina. Amlodipine-associated gingival hyperplasia was first reported in 1993.<sup>9</sup> Gingival hyperplasia has been mostly seen arising approximately 2 to 3 months after the use of amlodipine as observed in our case.<sup>10</sup>

Brown *et al.* in 1990 discussed a biochemical mechanism of this drug side effect pointing to decreased cellular folate uptake, leading to decreased catabolism, due to an insufficient amount of activated collagenase. Brown *et al.* again in 1991 further enlarged upon this mechanism discussion regarding a biochemical pathway hypothesis which is illustrated in the flowchart [Figure 2] below.<sup>11</sup>

While performing the examination of the oral mucosa, the clinician will observe a granular and pebbly gingiva, as distinctly seen in our case. This unsightly appearance has been referred to as ‘resembling clusters of grapes’, as the outer surfaces appear dotted with numerous smaller papillations.<sup>12</sup> Butterworth *et al.*<sup>13</sup> stated that the clinical manifestation of gingival overgrowth can range in severity from minor variations to complete coverage of the teeth, and that drifting of the teeth can occur, creating subsequent functional and aesthetic problems for the patient.<sup>12</sup>

The management of DIGO is mainly focused at upholding a good oral hygiene regimen to control the gingival inflammation for the interaction between the drug and the gingival tissues could be enhanced by gingival inflammation caused by poor oral hygiene. It has been shown that there was significant reduction of DIGO by thorough scaling and root planning and scrupulous plaque control.<sup>14</sup> Surgical reduction of the overgrown tissues is frequently necessary to accomplish an aesthetic and functional

outcome. The treatment may consist of surgical gingivectomy and/ or laser gingivectomy, although recurrence rates with this procedure is as high as 40%.<sup>14-15</sup> Laser on the other hand is one of the most promising new technical modalities in periodontal treatment having strong hemostatic and bactericidal effect and providing a relatively dry field which aids in improved visibility.<sup>14</sup>

Discontinuation of the related drug has been shown to reduce DIGO, however the growth recurs when the drug is re-administered. In cases where alternate medication can be used, substitution in the related drug has proved to result in regression of the overgrowth as was in our case.<sup>14</sup> Thus, depending on the severity of the case and the patients level of discomfort; either surgical or non-surgical option can be considered as a viable treatment option. However, non-surgical therapy typically requires between 2 and 3 months for the effects to be clinically apparent, while a surgical approach allows for more rapid results, with immediate patient satisfaction.<sup>16</sup>

## CONCLUSION

It is an aptly known proverb that ‘every coin has two sides’. So as the prescription for CCBs has increased considerably over the years, so has the occurrence of its possible side-effects which includes DIGO. As we all can unanimously pledge that prevention is always better than cure; so, there is a fundamental need for physicians and dentists to make a coordinated treatment plan for the patients indicated for these drug therapies. Alternate drug regime in various medical conditions can indeed yield a better balance of both the medical and dental health of the patient. For clearly, we all will support the situation in which when the coin is flipped the scenario stands: ‘Heads we win and tails we neither lose’.

## REFERENCES

1. Fermin AC, Eva LH. Gingival Enlargement. In, Newman, Takei, Carranza and Klokkevd. Carranza’s Clinical Periodontology, 10th Edition. St Louis, Saunders Publishers. 2006:373-90.
2. Ambicki M, Brodowski R, Mucha M, Migut M, Malawski-Rog A, Stopyra W, *et al.* Drug-Induced Gingival Overgrowth after Cyclosporin A Therapy. *Eur J Clin Exp Med.* 2017;15(1):82-6.
3. Seymour RA, Ellis JS, Thompson JM, Monkman S, Idle JR. Amlodipine Induced Gingival Overgrowth. *J Clin Periodontol.* 1994;21(4):281-3.
4. Khan S, Mittal A, Kanteshwari IK. Amlodipine Induced Gingival Overgrowth: A Case Report. *NJDSR.* 2012;1:65-9.
5. Ghafari A, Poorabbas R, Takieh JA, Sepehrvand N, Kargar C, Hatami S. Gingival Enlargement and its Risk Factors in Kidney Transplant Patients Receiving Cyclosporine A. *Iran J Kidney Dis.* 2010;4(1):66-70.
6. Bokenkamp A, Bahuharst B, Beier C, Albers N, Offner G, Brondehl J. Nifedipine Aggravates Cyclosporine A-Induced Gingival Hyperplasia. *Pediatr Nephrol.* 1994;8(2):181-5.
7. Walsh E, Abdelsalem A, Maccarthy D. Case Report: Drug-Induced Gingival Overgrowth Associated with the Use of a Calcium Channel Blocker. *J Ir Dent Assoc.* 2015;61(5):248-51.
8. Aldemir NM, Begenik H, Emre H, Erdur FM, Soyoral Y. Amlodipine-Induced Gingival Hyperplasia in Chronic Renal Failure: A Case Report. *Afr Health Sci.* 2012;12(4):576-8.
9. Ellis JS, Seymour RA, Thomason JM, Monkman SC, Idle JR. Gingival Sequestration of Amlodipine Induced Gingival Overgrowth. *Lancet.* 1993;341(8852):1102-3.
10. Meraw SJ, Sheridan PJ: Medically Induced Gingival Hyperplasia. *Mayo Clin Proc.* 1998;73(12):1196-9.
11. Brown RS, Arany PR. Mechanism of Drug-Induced Gingival Overgrowth Revisited: A Unifying Hypothesis. *Oral Dis.* 2015;21(1):51-61.
12. Thompson AL, Herman WW, Konzelman J, Collins MA. Treating Patients with Drug-Induced Gingival Overgrowth. *J Dent Hyg.* 2004;78(4):1-13.
13. Butterworth C, Chapple I. Drug-Induced Gingival Overgrowth: A Case with Auto-Correction of Incisor Drifting. *Dent Update.* 2001;28(8):411-6.
14. Taib H, Ali TB, Kamin S. Amlodipine-Induced Gingival Overgrowth: A Case Report. *Archives of Orofacial Sciences.* 2007;2:61-4.
15. Kendall P, Pugashetti JV, Aronowitz P. Drug-Induced Gingival Overgrowth after Renal Transplantation. *J Gen Intern Med.* 2017;32(12):1406.
16. Mathur S, Khatri RK, Mathur R, Srivastava R, Nag BP. Drug Induced Gingival Overgrowth: A Rare Case Report. *J Clin Diagn Res.* 2015;9(1):31-3.

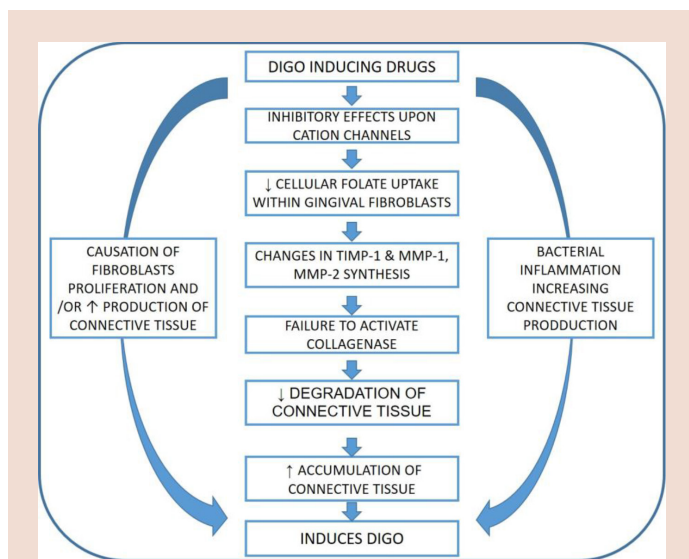


Figure 2: Flow-Chart showing the Mechanism of DIGO.